



# EMS System for Metropolitan Oklahoma City and Tulsa 2017 Medical Control Board Treatment Protocols



Approved 11/9/16, Effective 2/1/17, replaces all prior versions

## 2J – CONFIRMATION OF ENDOTRACHEAL AIRWAY PLACEMENT ADULT

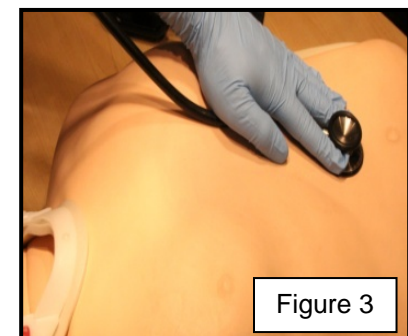
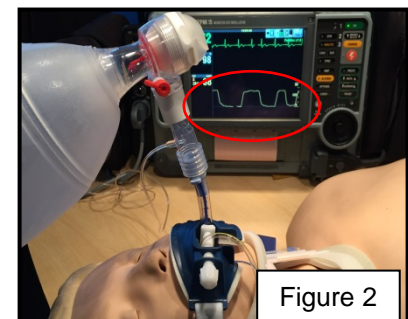
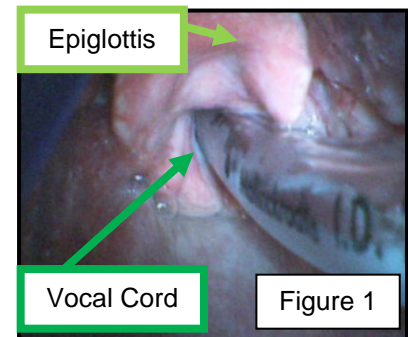
EMT-INTERMEDIATE 85

ADVANCED EMT

PARAMEDIC

The following sequence is to be used (and its use documented) to verify and maintain correct endotracheal artificial airway placement without fail:

1. **Visualization of endotracheal tube passage between vocal cords – oral intubation only.** (Figure 1)
2. **Detection of End-tidal carbon dioxide.** End-tidal carbon dioxide (EtCO<sub>2</sub>) detection shall be confirmed within 60 seconds of endotracheal tube placement. The capnography adaptor is to be placed at the bag-valve device-endotracheal tube interface for the first ventilation. The normal waveform indicating correct endotracheal placement reflects a rapid upstroke with the beginning of exhalation, the exhalation plateau ending at the point of EtCO<sub>2</sub> measurement, and a rapid downstroke with the beginning of inhalation. Any waveform that does not show rhythmic rise and fall correlating with assisted ventilations indicates incorrect tube placement and the tube must be withdrawn. **To be perfectly clear, the use of an endotracheal tube for ongoing oxygenation and ventilation is dependent upon continuously measurable capnography waveforms.** See Protocol 3H -Capnography for discussion of EtCO<sub>2</sub> values and waveforms. (Figure 2)
3. **Auscultation. Auscultate the epigastrium.** (Figure 3) If epigastric sounds are heard, intubation is to be reattempted. The endotracheal tube placed in the esophagus may be left in place, at the intubator's discretion, until another endotracheal tube is correctly placed and verified. If no epigastric sounds are heard, proceed to **auscultation of the thorax bilaterally.** Breath sounds are best auscultated in the anterior to mid-axillary lines. If breath sounds are present on the right and absent on the left, this suggests a right mainstem intubation. Withdraw the endotracheal tube 1 cm and repeat breath sound auscultation. If necessary, the tube may be withdrawn an additional 1-2 cm.





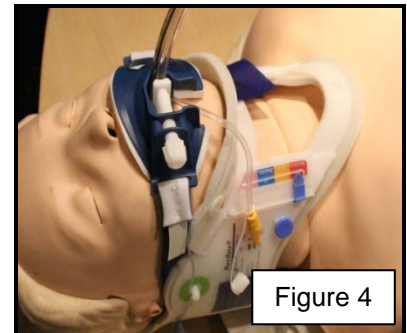
## EMS System for Metropolitan Oklahoma City and Tulsa 2017 Medical Control Board Treatment Protocols



Approved 11/9/16, Effective 2/1/17, replaces all prior versions

### PROTOCOL 2J: Confirmation of Endotracheal Artificial Airway Placement – Adult

4. **Assessment of physiologic changes.** These include equal rise and fall of the chest, condensation in the endotracheal tube on exhalation, improvement in the patient's color, and improvement in the patient's respiratory distress/failure.
5. **Secure the endotracheal tube with a tube holder and place a cervical collar.** (Figure 4)



When intubated patients are moved during EMS care, waveform capnography must be rechecked for any change. If the waveform continues to show a normal pattern of rapid upstroke with exhalation, exhalation plateau, and rapid downstroke with inhalation, no further repeat confirmation is required. If at any time, the capnography waveform is abnormal, steps 2-5 must be rechecked and documented. If at any time during patient care there is doubt as to correct endotracheal placement of intubation, either re-verify by this sequence or reattempt correct endotracheal placement. While the intubator may delegate confirmation steps to his/her colleagues, he or she is ultimately responsible to ensure that a complete confirmation sequences performed. If the intubator accompanies the patient to the hospital, he or she remains ultimately responsible for ongoing endotracheal tube placement confirmation. If the intubator does not accompany the patient to the hospital by ambulance or helicopter ambulance transport, the primary transporting/treating paramedic or RN assumes ultimate responsibility for ongoing endotracheal tube placement confirmation.

Upon delivery of the patient at treatment destination or at subsequent transport (eg. helicopter transport), a waveform capnograph will be obtained and documented after the patient has been physically transferred onto the destination's/subsequent transport's stretcher/bed/operating table to show confirmed, continued correct endotracheal tube placement at EMS transfer of patient care.